

## Is Surgical Navigation the Answer and Is Real Time Intra-operative Documentation Needed?

By H.M. Reynolds, M.D. and Timothy McTighe, Ph. D.



There has been growing interest in surgical navigation in part due to continued problems with dislocation. Dislocation have been reported in primary surgeries from 1-10% and as high as 29% in revisions. This senior author has revised over a hundred loose cementless cups just in the past year due to a well known recall of hip implants with fabrication problems. These have increased our dislocation rate from 2% to over 20%. Many of these revised cups present significant problems in determining proper cup orientation, cup stability, and added problems to joint stability due to compromised soft tissue integrity.

Intense and excess rehab, along with reduced levels of activity, post-op bracing and modification of life styles have allowed some patients to go back into reduced normal physical routines.

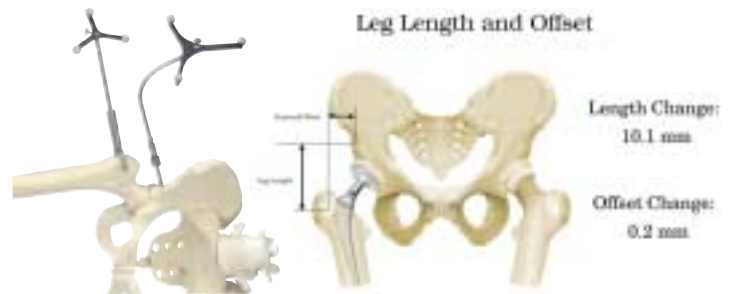
Limb alignment, implant position and soft tissue balance have become significant problems. There is no easy and accurate way to track the relationship between pelvis and the femur during surgery. Certainly patient position and limitations of conventional instruments can affect cup positioning. Drapes obscure the patient and make leg alignment for orientation difficult. In addition we are often dealing with significant loss of bone and orientation landmarks.

Leg length measurement is difficult at best. Pelvic tilt can confound intra-op leg length checks. One solution would be to use trackers fixed to the pelvis and femur that can record their relationship to dislocation to ensure the desired leg length and femoral offset is achieved.

This intra-operative documentation system will provide real time feed back that will aid the surgeon in knowing where he is and where he needs to go to correct the biomechanical aspects of his hip reconstruction. Possible additional benefits of such a system would be to document surgical results such as cup position (abduction=45°), (anteversion=20°); femoral offset 45 mm, leg length +2mm and femoral version angle 15°.

Printouts for posting in the patient's chart should immediately be made available, reducing the chance of error during transcription.

A simple reproducible system of documenting limb alignment and implant orientation that does not require special operators or expensive preoperative preparation and does not add more than ten minutes to current OR time would be a system that could have a positive affect on outcomes.



One such system is the NaviPro™ System from Kinamed. This system is based on digital technology. It allows for checking relationship between femur and pelvis before and after implantation without imaging technologies. Basic components include a mobile trolley cart that holds a stereo camera, low-profile computer, flat-panel display, foot controls and a mini-printer.

Surgical instruments include passive trackers for the pelvis, femur and a calibrated probe. The technique requires location and marking pelvic landmarks, both ASIS joints, and the Mid-Pubis. Draping, soft-tissue or the patient holder may obscure landmarks. A calibrated patient holder is helpful for the posterior approach. Recording the native pelvis-femur relationship prior to dislocation can be done with manual manipulation of the leg.

At this point standard surgical technique for acetabulum preparation is carried out. During insertion of the trial cup, a tracking probe can be attached to the shaft of the cup impactor and cup position can be registered by engaging a foot pedal. The LED screen provides real-time feedback on cup position (abduction & anteversion).

A tracking device is attached to the greater trochanter for referencing leg length and femoral offset. Standard femoral preparation of the femur is carried out and with femoral trials in place, the reduced hip measurement is carried out by a click of the foot pedal. The NaviPro™ software computes the new pelvic-femur relationship, registering leg length and offset.

A simple printout summarizes results of the surgical case accurately, documenting implant orientation and biomechanical restoration. We are excited about the prospects of this technology and will report our particular experience with it in the future.

