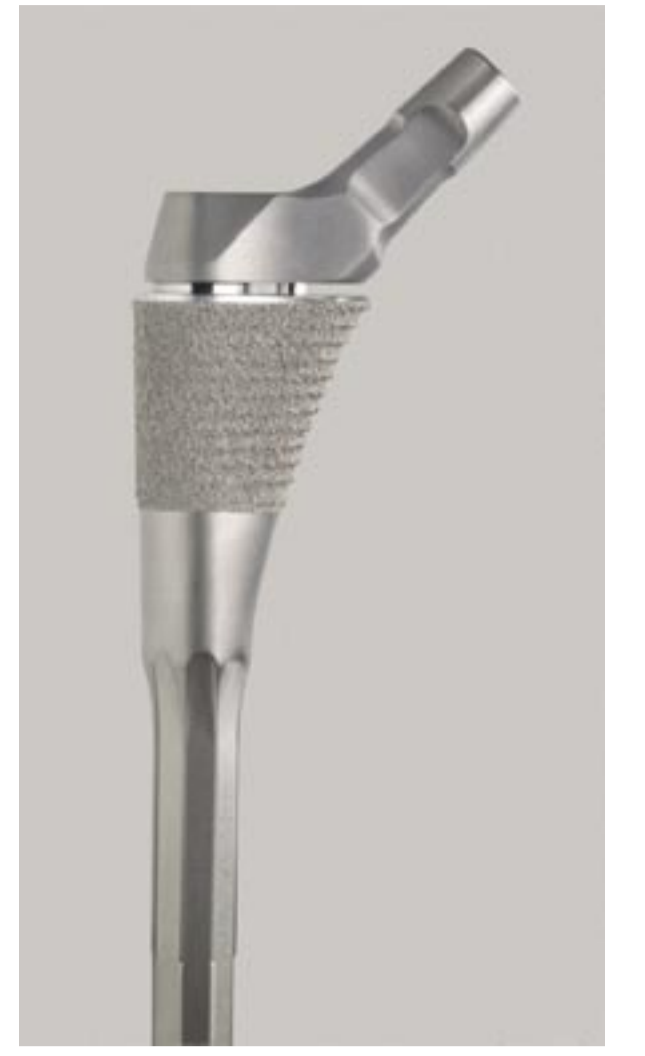



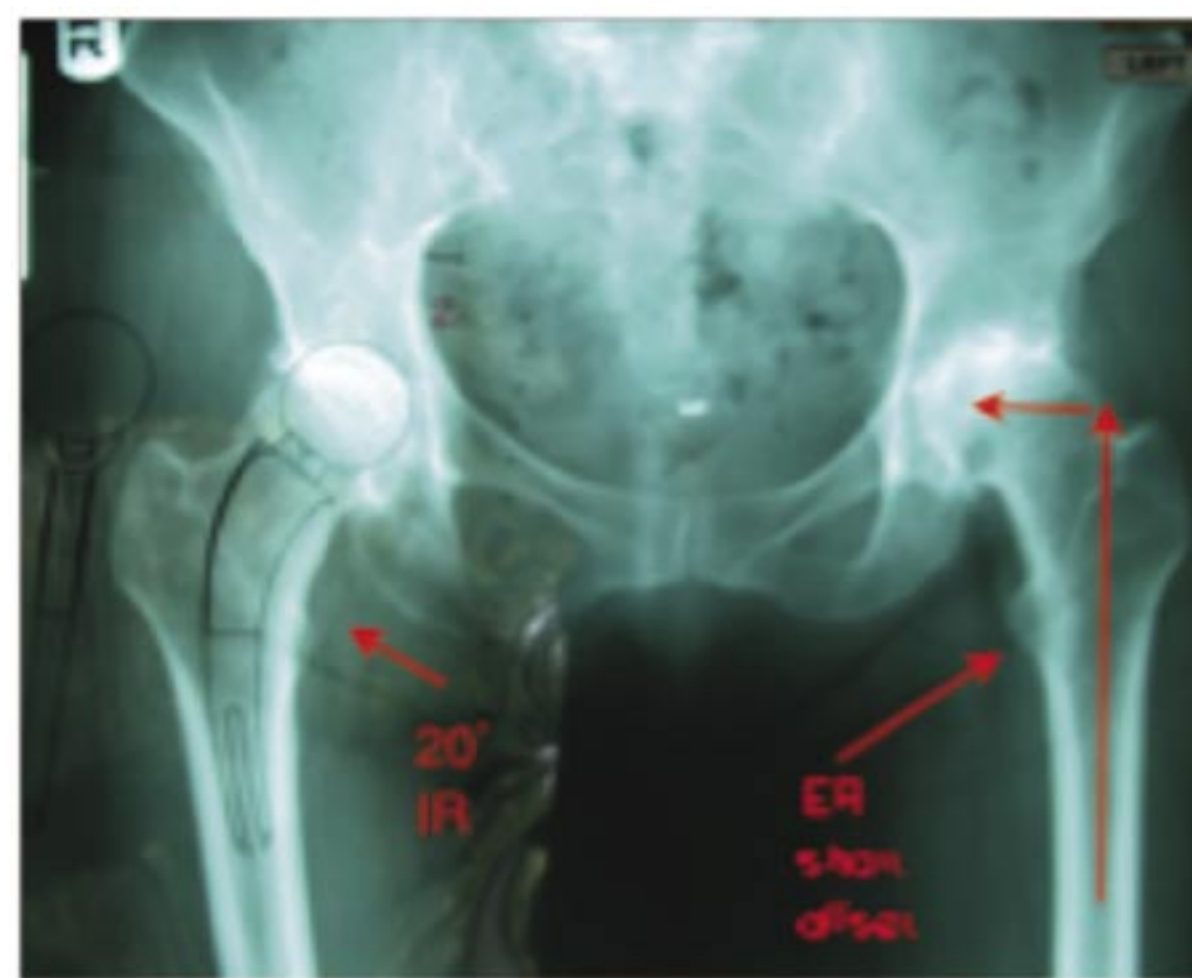# Intraoperative Techniques in Using Proximal Modular Stems

By: \*Thomas Tkach, MD, \*Warren Low, MD, and \*\*Timothy McTighe, PhD (hc)  
\* McBride Clinic, Oklahoma City, OK, USA  
\*\* Joint Implant Surgery & Research Foundation, Chagrin Falls, OH, USA



## Introduction

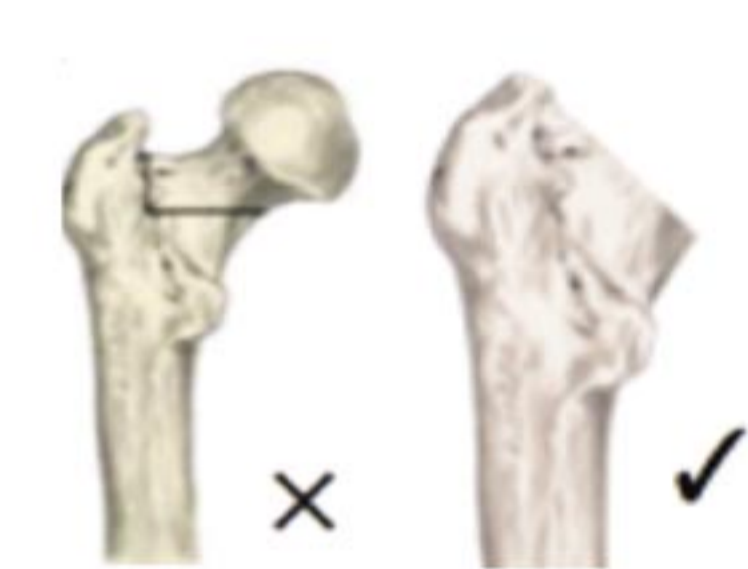Preoperative planning and proper communication saves valuable time and improves efficiencies and outcomes for each case. Do not assume that newer more sophisticated proximal modular stems have the same surgical flow as the historic monoblock stem designs. The proper staging of surgical procedures is often neglected or taken for granted resulting in added operating room time and risk for the patient. Examples: Will allograft or autograft be needed? Will intraoperative x-rays be needed? Will certain non-standardize instruments (Explant) be needed? Will additional personnel be needed and will there be a change of personnel if the case drags on? All of these, and more, can affect the flow and outcome of the surgical procedure especially when a change of devices occurs.



## Work From Accurate Radiographs

- 20° internal rotation shows correct femoral offset
- External rotation can be off as much as 1 cm in femoral offset measurement
- If necessary, measure from contra-lateral side

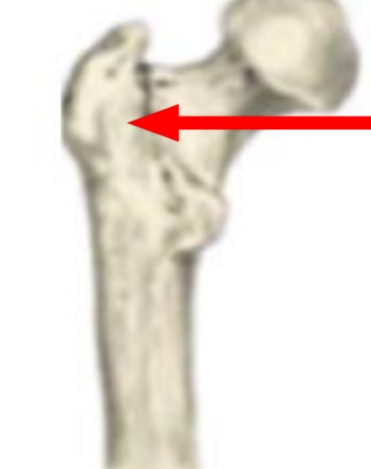## Surgical Technique For The Proximal “Dual Press™” Modular Stem Design



### Femoral Head Resection

Measure proximally from the lesser trochanter and mark the distance which corresponds to the proper resection level from pre-operative planning. Resect the neck. The resection should be directed obliquely and medially from the level marked above the trochanteric fossa.

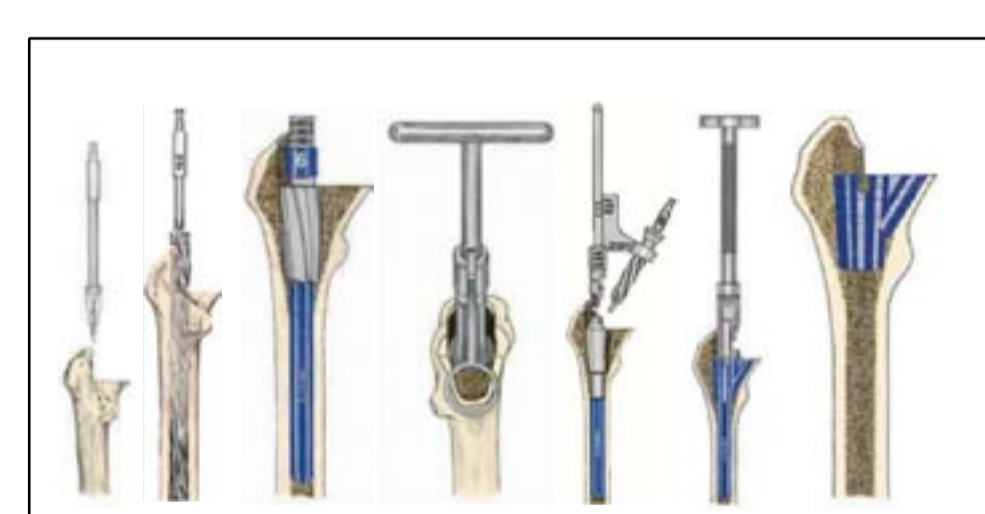
**Technique Tip:** A conservative cut is recommended here. Fine-tuning may be accomplished later in the procedure.



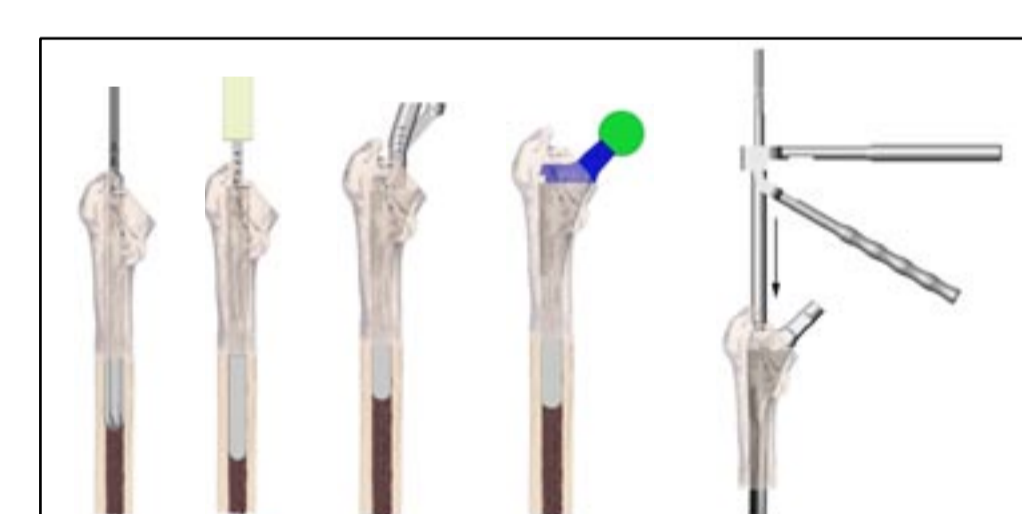A horizontal cut too far lateral can risk fracture of the Greater Trochanter.

Proximal modular technique is based off the historic S-Rom® technique with simplified instruments:

- Box chisel
- Distal ream
- Prox. cone ream
- Broach triangle
- Trial Implant



S-Rom™ surgical technique



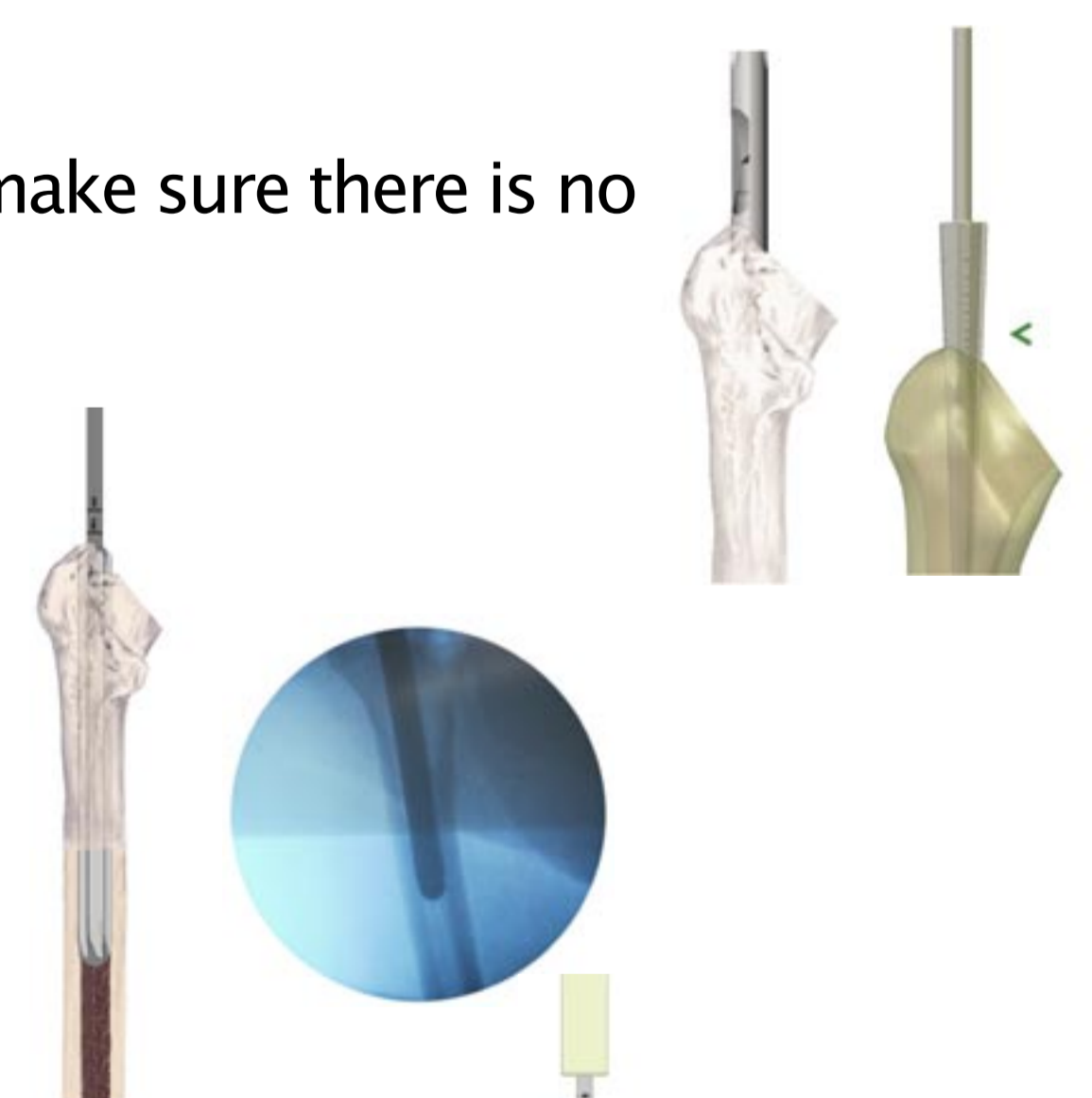
Simplified “Dual Press™” Stem technique

## Canal Entry

A box chisel or trochanteric reamer can be used – make sure there is no overhang from the trochanter.

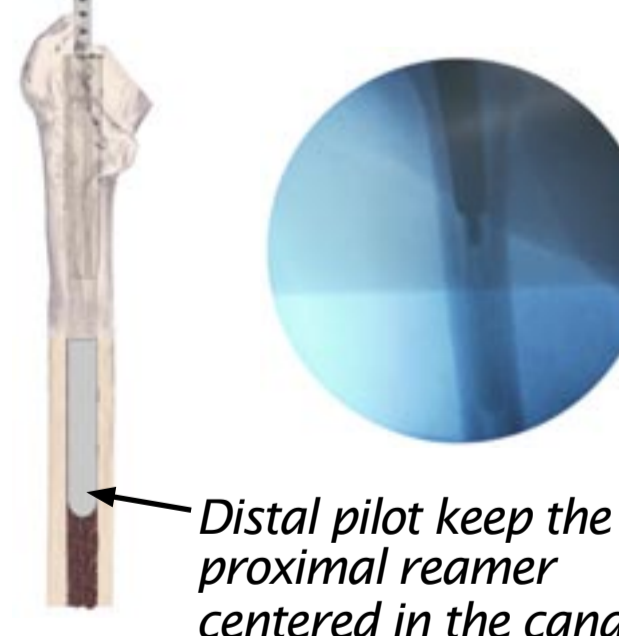
## Intramedullary Canal Reaming

Begin reaming using the 8mm reamer. Assure that the reamers are passed into the canal centrally and aligned correctly. Sequentially ream the intramedullary canal.



## Conical Reaming

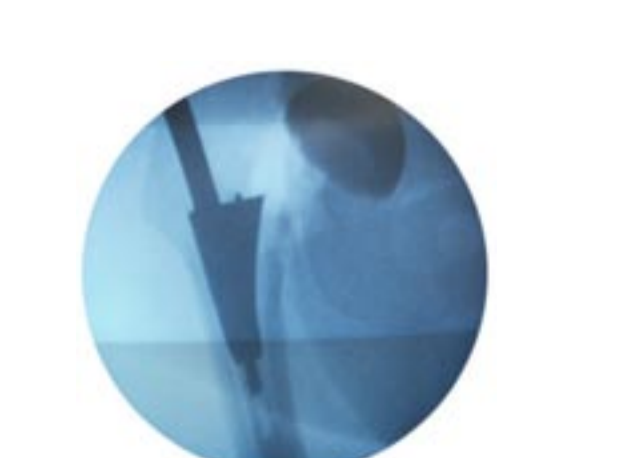Once the distal canal diameter is established, the proximal femur is prepared with a conical reamer followed by a broach to prepare for the medial spout.



Distal pilot keep the proximal reamer centered in the canal

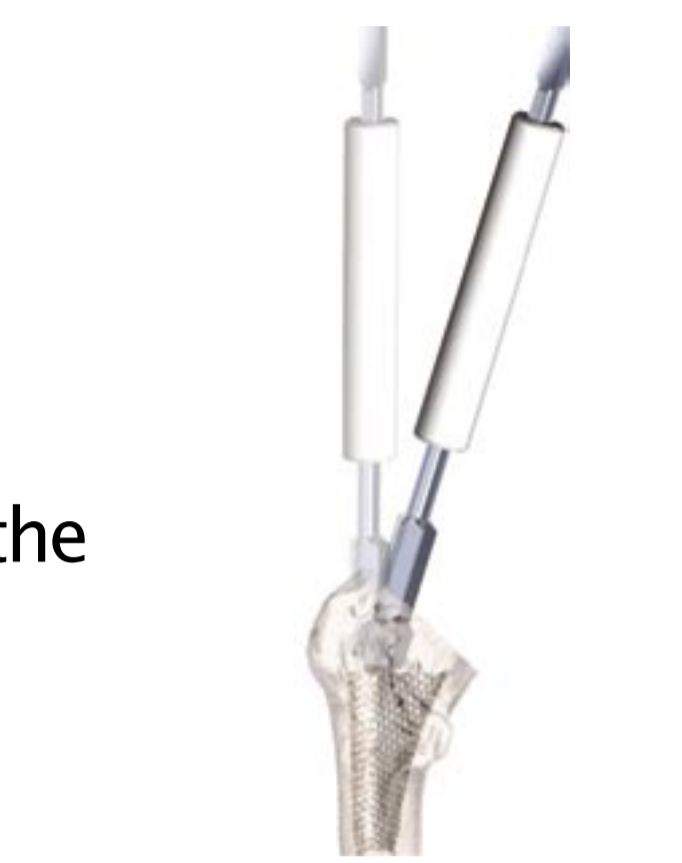## Medial Triangle Broaching

Start with the broach that is one or two sizes smaller than the last conical reamer. Attach the selected broach to the broach handle and then attach the appropriate stem pilot. Advance the broach to the depth established by the conical reamer and the neck resection plane. As with the conical reamers, reference marks to the greater trochanter are also provided on the broach handle.



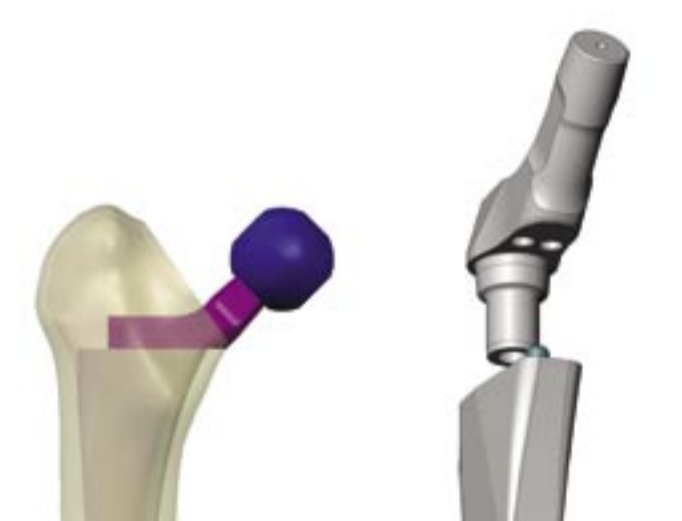
## Trochanter Clearance

A trochanteric reamer is provided in the instrument set to facilitate the placement of the modular neck trials and neck implants.



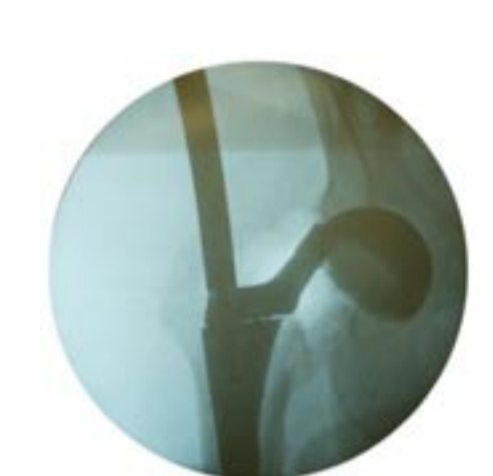## Trial Reduction

The modular neck trials slide onto the stud on the proximal end of the broach. Select the neck trial based on preoperative planning and on the previous intraoperative assessments. Slide the neck trial onto the broach, taking care to establish the proper version (0 or ±13 degrees anteversion).



## Implant Assembly

The device may be assembled on the back table or in situ depending on surgeon preference or surgical indication. The important feature to remember is that the surgeon has the last minute opportunity to fine-tune joint mechanics without disruption of implant-bone interface.

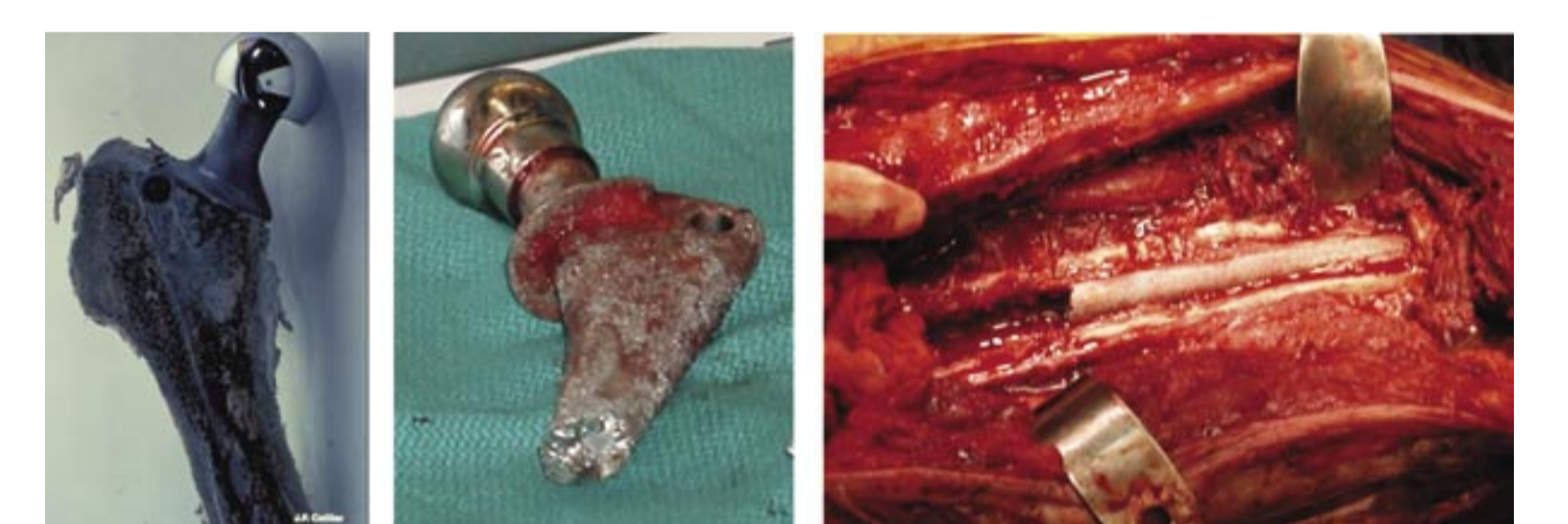

## Retrievability Features

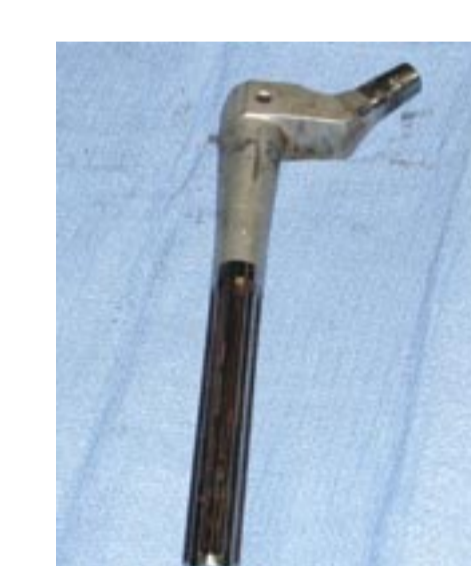It is a fact of life in orthopaedics, what goes in often has to come out. Older hip stem designs very often lack this basic understanding. Retrieval requires extensive surgical expertise and brings about significant damage to soft and hard tissues. With age comes experience and acknowledgment of the historical limits of previous work. Designing and developing procedures to retrieve loose, broken and or infected devices is a modern day requirement.

A distally well fixed stem, broken or not, is one of the most challenging revision surgical procedures.

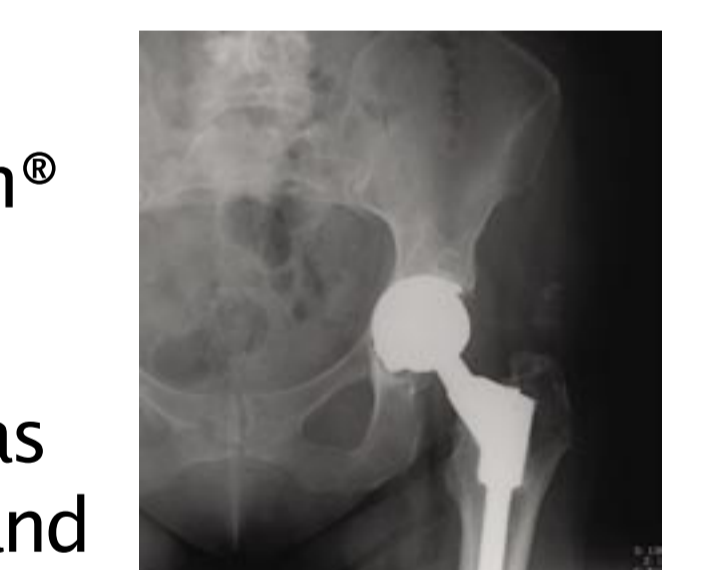A well fixed porous modular stem with bone ingrowth at the base of the proximal modular cone made this socket revision extremely difficult – in great part do to the obstruction caused by the femoral neck.



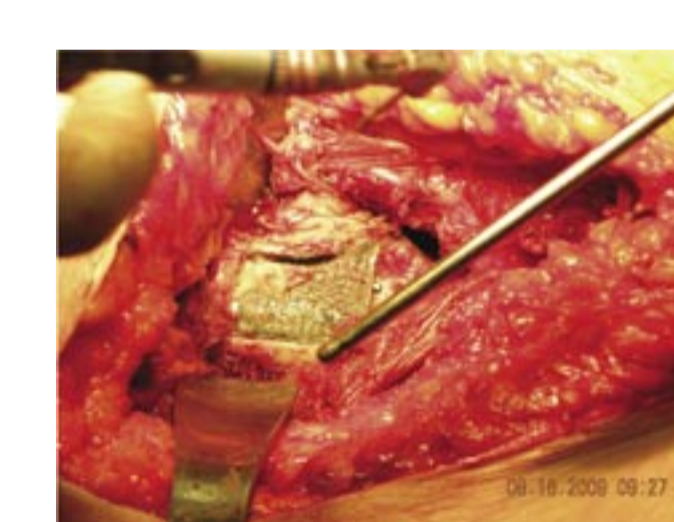
Anyone that has tried to remove a distal fluted device like the S-Rom® stem knows this is not easily accomplished.



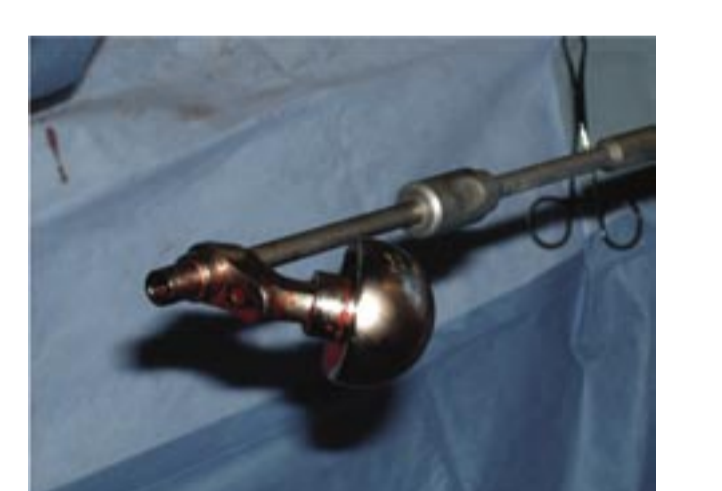The proximal modular “Dual Press™” stem design has some additional features that make removal easier and more reproducible compared to older stem designs. The proximal neck portion allows capture, and is disengaged from the stem body with direct axial force with a slap-hammer.



If the proximal body is bone ingrown a small window and dental burr aids in freeing up the proximal portion of the stem. (Keggi technique)



The stem body can then be directly engaged with the same removal tool that provides a solid lock onto the stem and with direct axial force applied by use of a slap-hammer.



Revisions are always with us so select a device that takes retrievability into account.



## Summary

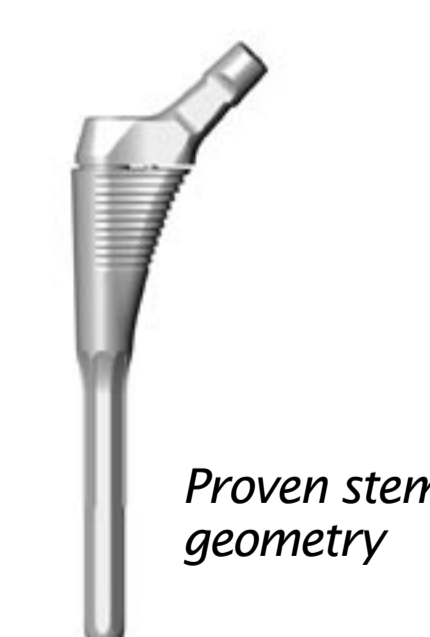
- Certainly modular designs goals have changed over the past 24 years. In the early 1980s fit & fill were the principal objectives.
- Today aseptic loosening does not have the same concern.
- The reduction of particulate debris and restoration of hip mechanics are the focal point.



Version adjustment



Femoral Offset



Proven stem geometry

