

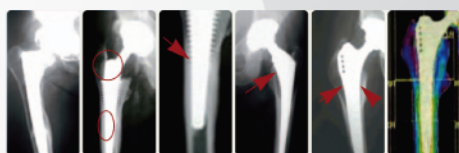Comparison of A Short, Stemless- and A Conventional Stemmed Total Hip Prostheses in Young Patients

Young-Hoo Kim, MD, Jun-Shik Kim, MD, Jang-Won Park, MD, and Jong-Hwan Joo, MD
The Joint Replacement Center of Korea, Ewha Womans University School of Medicine, Seoul, Korea

Disclosure: Senior author (YHK) receives royalties from Depuy, A Johnson & Johnson Company. Other co-authors did not receive any external funds for this study.

Conventional stemmed THA (Problems)

- ↑ stress shielding
- ↑ thigh pain



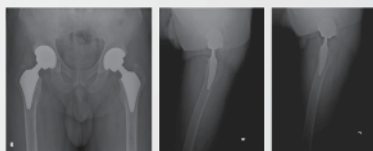
Short, stemless femoral component

- ↓ stress shielding
- ↓ thigh pain



Purpose of study

- To investigate whether short, stemless anatomic cementless femoral component would obtain strong fixation without diaphyseal anchorage as conventional anatomic stem
- To investigate whether short, stemless anatomic cementless femoral component would ↓ the prevalence of thigh pain and stress shielding



Proxima stem

- Titanium alloy
- Porous-coated \bar{c} Ti beads (250 μ m)
- HA-coated (30 μ m)
- Femoral neck cut at head-neck juncture
- Pronounced lateral flare



Profile stem

- Titanium alloy
- Anatomic metaphyseal and diaphyseal filling stem
- Porous-coated \bar{c} Ti beads (250 μ m) (proximal 1/3)



Materials and Methods (Cup)

Cup

- Pinnacle with Biolox forte-on-Biolox forte (28 mm liner) : All hips

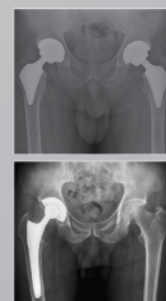


Proxima group

- 50 pts (60 hips)
- M/F : 22/28
- Age (yrs) : 54.3 (26-60)
- Dx. (Pts)
 - OA : 24 (48%)
 - ON : 18 (36%)
 - TA : 5 (10%)
 - Neck Fx. : 3 (6%)
- FU (yrs) : 3.3 (3-4)

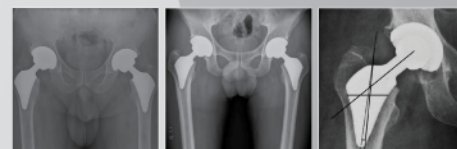Profile group

- 50 pts (60 hips)
- M/F : 24/26
- Age (yrs) : 51.8 (21-60)
- Dx. (Pts)
 - OA : 24 (48%)
 - ON : 22 (44%)
 - TA : 3 (6%)
 - Neck Fx. : 1 (2%)
- FU (yrs) : 3.3 (3-4)



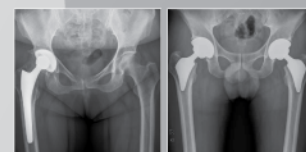
Clinical (HHS) and X-ray FU

- 3 mons
- 1 year
- Annually



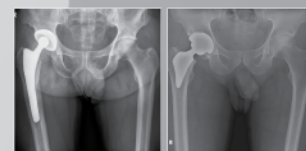
Loosening of stem (Definite)

- Axial subsidence : > 2 mm
- Varus or valgus shift : > 2°



Loosening of stem (Possible)

- Complete RLL surrounding porous-coated surface on both AP and lateral x-rays

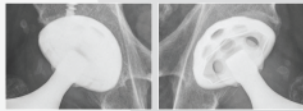


Comparison of A Short, Stemless- and A Conventional Stemmed Total Hip Prostheses in Young Patients

Young-Hoo Kim, MD, Jun-Shik Kim, MD, Jang-Won Park, MD, and Jong-Hwan Joo, MD
The Joint Replacement Center of Korea, Ewha Womans University School of Medicine, Seoul, Korea

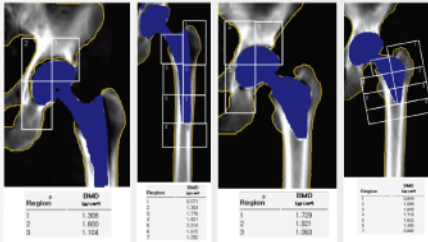
Loosening of cup

- Position change (> 2 mm)
- Continuous RLL (> 2 mm)



DEXA examination

- 1 week
- Final FU



Revision (Cup and stem)

- 0 hip in both groups

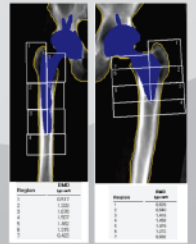
DEXA examination (at 3 yrs)

Proxima

- zone 1 : significantly ↑ (9%) (p=0.001)
- zone 7 : slightly ↓ (10%) (p=0.177)

Profile

- zone 1 : significantly ↓ (30.3%) (p=0.00001)
- zone 7 : significantly ↓ (32.8%) (p=0.00001)



Results

HSS

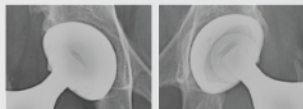
	Proxima	Profile	P-value
Preop :	44.6	48.4	0.124
Postop :	97	96	0.790

Thigh pain

- Proxima : 0 % (0 pt.)
- Profile : 10% (5 pts)

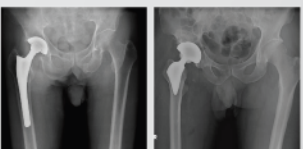Fixation of cup

- Bone ingrown : all hips in both groups



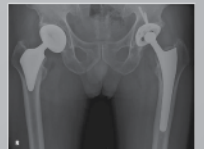Fixation of stem

- Bone ingrown: all hips in both groups



Bone remodeling (X-rays)

- Proxima : Grade 1 (all hips)
- Profile : Grade 3 (15 hips)
Grade 4 (45 hips)



Discussion

- The geometry of this short, stemless anatomic neck sparing cementless femoral stem (Proxima) has proved to provide effective initial stability without the diaphyseal anchorage
- Femoral neck preservation and lateral flare of the Proxima stem provide an axial and a torsional stability and more natural loading of the proximal femur

Conclusions

- The short, stemless anatomic Proxima femoral component achieved as adequate a level of fixation in the proximal femur as did the Profile conventional stemmed femoral component, but it provided significantly less stress shielding bone resorption than the Profile femoral stem